

ORIGINAL RESEARCH

ANCD thrombectomy device: in vitro evaluation

Sonia Sanchez,¹ Ignacio Cortiñas,¹ Helena Villanova,¹ Anna Rios,¹ Iñaki Galve,¹ Tommy Andersson,^{2,3} Raul Nogueira,⁴ Tudor Jovin,⁵ Marc Ribo^{6,7}

► Additional material is published online only. To view please visit the journal online (<http://dx.doi.org/10.1136/neurintsurg-2019-014856>).

¹R&D, Anaconda Biomed, Barcelona, St Cugat del Valles, Spain

²Departments of Radiology and Neurology, AZ Groeninge, Kortrijk, Belgium

³Departments of Neuroradiology and Clinical Neuroscience, Karolinska University Hospital, Karolinska Institutet, Stockholm, Sweden

⁴Department of Neurology, Emory University School of Medicine, Atlanta, Georgia, USA

⁵Department of Neurology, UPMC, Pittsburgh, Pennsylvania, USA

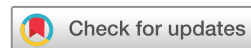⁶Stroke Unit, Neurology, Hospital Vall d'Hebron, Barcelona, Spain

⁷Universitat Autònoma de Barcelona, Barcelona, Spain

Correspondence to

Dr. Marc Ribo; marcriboj@hotmail.com

Received 1 April 2019
Revised 14 May 2019
Accepted 14 May 2019



© Author(s) (or their employer(s)) 2019. No commercial re-use. See rights and permissions. Published by BMJ.

To cite: Sanchez S, Cortiñas I, Villanova H, et al. *J NeuroIntervent Surg* Epub ahead of print: [please include Day Month Year]. doi:10.1136/neurintsurg-2019-014856

ABSTRACT

INTRODUCTION

Endovascular treatment of stroke, although highly effective, may fail to reach complete recanalization in around 20% of cases. The Advanced Thrombectomy System (ANCD) is a novel stroke thrombectomy device designed to reduce clot fragmentation and facilitate retrieval by inducing local flow arrest and allowing distal aspiration in combination with a stent retriever. We aimed to assess the preclinical efficacy of ANCD.

Methods Soft red blood cell (RBC)-rich (n=20/group) and sticky fibrin-rich (n=30/group) clots were used to create middle cerebral artery (MCA) occlusions in two vascular phantoms. Three different treatment strategies were tested: (1) balloon guide catheter + Solitaire (BGC+SR); (2) distal access catheter + SR (DAC+SR); and (3) ANCD+SR, until complete recanalization was achieved or to a maximum of three passes. The recanalization rate was determined after each pass.

Results After one pass, ANCD+SR resulted in an increased recanalization rate (94%) for all clots together compared with BGC+SR (66%; p<0.01) or DAC+SR (80%; p=0.04). After the final pass the recanalization rate increased in all three groups but remained higher with ANCD+SR (100%) than with BGC+SR (74%; p<0.01) or DAC+SR (90%; p=0.02). The mean number of passes was lower with ANCD+SR (1.06) than with BGC+SR (1.46) or DAC+SR (1.25) (p=0.01). A logistic regression model adjusted for treatment arm, clot type, and model used showed that both RBC-rich clots (OR 8.1, 95% CI 1.6 to 13.5) and ANCD+SR (OR 3.9, 95% CI 1.01 to 15.8) were independent predictors of first-pass recanalization.

Conclusion In in vitro three-dimensional models replicating MCA-M1 occlusion, ANCD+SR showed significantly better recanalization rates in fewer passes than other commonly used combinations of devices.

Endovascular treatment (EVT) is recognized as the most effective treatment for large vessel occlusion (LVO) strokes.¹ The highest degree of recanalization² in the shortest time^{3,4} with the minimum number of attempts⁵ has been shown to correlate with improved clinical outcomes. Although highly effective, failure to reach complete recanalization has been reported in about 20% of treated patients.^{2,6}

Recent efforts have been put forward to understand the mechanism of failure during EVT,^{7,8} which may be due to: (1) fibrin-rich clots, which have a high coefficient of friction and seem to be more difficult to aspirate or grab with a stent retriever⁹; (2) hard calcium or cholesterol-containing clots that

may be wedged and stuck and that will not fit into the extracting catheter; or (3) fragile red blood cell (RBC)-rich clots prone to fragmentation and detachment during retrieval or when entering the accepting catheter.¹⁰ In addition to the difficulties posed by resistant clots causing failure or necessitating multiple passes to achieve a satisfactory reperfusion outcome, embolic fragmentation remains a major challenge to the success of reperfusion. Distal aspiration catheters with large bore sizes¹¹ and balloon guide catheters (BGC)¹² to achieve flow arrest have been progressively developed and increasingly used during recent years with the aim of improving the technical success of EVT.

The Advanced Thrombectomy System (ANCD) is a novel stroke thrombectomy device designed to reduce clot fragmentation and facilitate retrieval by inducing local flow arrest and allowing distal aspiration in combination with a stent retriever. We aimed to assess the preclinical efficacy of ANCD in two different vascular phantoms.

METHODS

The model system is composed of a human cerebrovascular replica including a clot model and a physiologically relevant mock circulation flow loop. Two different vascular replicas were used: (1) Moderate Tortuosity (Jacobs Institute, Buffalo, New York, USA¹³ with tortuosity indexes¹⁴ intracranial 4.75 and global 7.08), and (2) Severe Tortuosity (University of Massachusetts, Worcester Massachusetts, USA¹⁵ with tortuosity indexes intracranial 5.83 and global 5.88). The replicas included both the carotid arteries and the posterior circulation. Each internal carotid artery (ICA) included the posterior communicating artery, the anterior cerebral artery (ACA), and the middle cerebral artery (MCA) including the M2 divisions. The MCA-M1 (average diameter 3 mm) and M2 divisions (average diameter 2 mm) were designed to rejoin distally, resulting in a single output.

Clot models were chosen to simulate the mechanical thrombectomy procedure in two different case scenarios: fibrin-rich/resistant and RBC-rich/fragile. The clot analogues were produced from porcine blood based on the methodology previously described.^{16,17} The individual clots were cut into 5 mm×7 mm pieces (diameter×length) and injected into the flow loop of the vascular replica to facilitate M1 occlusions. The cerebrovascular replica was connected to the flow loop with continuous monitoring of the MCA flow and pressure to ensure physiologically accurate hemodynamics. The flow loop contained a peristaltic pump (Harvard

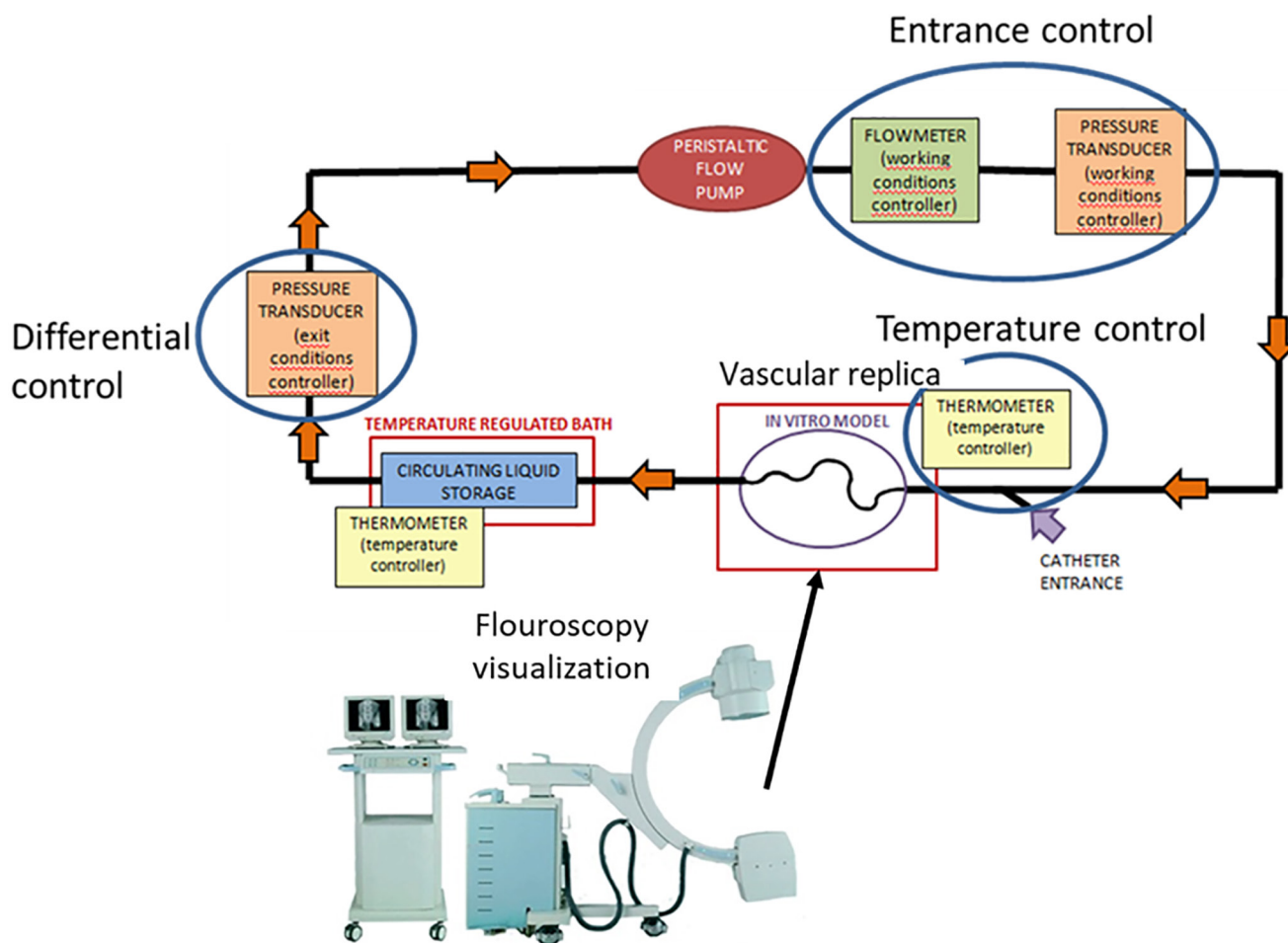


Figure 1 Flow model representation.

Apparatus), which was set to deliver a flow of saline solution heated to 37°C, and hosecock compressor clamps to provide peripheral resistance. By adjusting the peripheral resistance, the baseline flow conditions were matched to normal human phase measurements for each of the vessels, creating a hemodynamically representative cerebrovascular model. The flow rate in the full cerebrovascular replica was set at 370–450 mL/min, values based on physiological flow rates. The system pressure was also regulated and set to 180 mmHg (Gage electronic pressure transducer, Valydine), which is within the upper range of clinically representative blood pressure. Flow and pressure sensors were positioned at the entrance to the circuit after the peristaltic pump output, while a second pressure sensor was positioned after the vascular replica, calculating the differential pressure (Electronic High Precision Flow Meter, Titan). A digital thermometer measured the fluid temperature in the mid zone of the replica (figure 1). Intravascular devices were maneuvered under fluoroscopic guidance and angiographic images of the vessels were obtained to identify the proper location of the device (fluoroscopy equipment: OEC Fluorostar 7900, GE Healthcare and BV Pulsera, Phillips).

RBC-rich (n=20/treatment group) and fibrin-rich (n=30/treatment group) clots were used to create MCA-M1 occlusions in the two different vascular phantoms. Clot type distribution according to treatment arm or vascular phantom is shown in table 1.

Three different treatment strategies were tested: (1) balloon guide catheter (BGC: 8F Cello; Medtronic Neurovascular) with the tip placed at the cervical ICA + stent retriever (SR: Solitaire FR 6×20 mm; Medtronic Neurovascular); (2) distal access




Figure 2 (+ online supplementary video). The Advanced Thrombectomy System (ANCD) device + stent retriever + clot after a thrombectomy. (1) Stent retriever; (2) ANCD covered funnel; (3) ANCD aspiration catheter; (4) ANCD delivery catheter.

Table 1 Study design and rate of complete recanalization after one pass and after the last pass (maximum of three passes)

Cerebrovascular model		BGC+SR			DAC+SR			ANCD+SR		
Tortuosity index	Clot type	n	1 pass, %	3 passes, %	n	1 pass, %	3 passes, %	n	1 pass, %	3 passes, %
Moderate										
Intracerebral: 4.752	Soft red	10	100	100	10	80	90	10	100	100
Global: 7.048	Fibrin rich	15	33	33	15	80	87	15	87	100
Severe										
Intracerebral: 5.831	Soft Red	10	80	80	10	90	100	10	100	100
Global: 5.878	Fibrin rich	15	67	93	15	73	87	15	100	100
	Total	50	66	74	50	80	90	50	94	100

BGC, balloon guide catheter; DAC, distal access catheter; SR, stent retriever.

catheter (DAC: 6F Navien; Medtronic Neurovascular) through a 6F conventional guide catheter (CGC: Neuron Max; Penumbra) with the tip placed at the cervical ICA+SR; and (3) ANCD (ANCD; Anaconda Biomed) through a 6F CGC (Neuron Max; Penumbra) with the tip placed at the cervical ICA+SR. In all groups, a microcatheter (Rebar 18, Medtronic Neurovascular) was advanced over a 0.014 inch microguidewire (Synchro; Stryker) to the proximal aspect of the occluding clot at the MCA-M1 level. In group 1, the BGC was inflated to arrest flow in the ICA before thrombectomy was performed. In group 2, after SR deployment, the DAC was advanced up to the proximal MCA-M1 segment before thrombectomy was performed. In group 3, the ANCD delivery catheter was advanced to the proximal MCA-M1 and the funnel deployed proximal to the clot creating local flow arrest. The microcatheter was then advanced through the clot and the SR deployed as in usual practice. At this point the microcatheter was completely withdrawn to increase aspiration force¹⁸ through the ANCD funnel catheter. The SR was then slowly pulled until its proximal end was inside the ANCD funnel, aspiration was initiated, and the SR+ANCD were progressively conjunctively pulled out (figure 2 + online supplementary video).

In all groups, aspiration during the thrombectomy procedure was performed with a 60 mL syringe (Vaclock; Merit Medical) connected to a three-way stopcock through either the BGC (1), the DAC (2), or the ANCD funnel catheter (3). For each clot, recanalization attempts with the same strategy were repeated until complete recanalization (Thrombolysis in Cerebral Infarction (TICI) 2b–3) was achieved or a maximum of three passes was reached (last pass). An angiography run was performed after each pass to assess recanalization. First- and last-pass recanalization rates were used in the analysis. Due to the nature of the flow models, the recanalization grade after each pass was dichotomized as complete (TICI 2b–3) or no recanalization (TICI 0–2a, at least one MCA-M2 branch remained occluded).

Statistical analysis

Frequency statistical analysis was obtained and comparisons were made using the SPSS 17.0 statistical package. Statistical significance for intergroup differences was assessed by the Pearson χ^2 test or the Fisher exact test for categorical variables and the Student's t-test and analysis of variance for continuous variables. When indicated, Mann–Whitney U tests and Spearman tests were used. Multivariate logistic regression analysis was performed to determine factors that could be considered independent predictors of first pass recanalization. A p value of <0.05 was considered significant for all tests.

RESULTS

A total of 150 thrombectomies were performed, 50 for each treatment group including 20 RBC-rich and 30 fibrin-rich clots. The rate of complete recanalization after one pass was higher with ANCD+SR (94%) than with BGC+SR (66%; $p<0.01$) or DAC+SR (80%; $p=0.04$). After the final pass the recanalization rate increased in all three groups, remaining higher with ANCD+SR (100%) compared with BGC+SR (74%; $p<0.01$) or DAC+SR (90%; $p=0.02$). The mean number of passes in each treatment group was lower with ANCD+SR (1.06) than with BGC+SR (1.46) or DAC+SR (1.25) ($p=0.01$).

For RBC-rich clots, the recanalization rates were not significantly different between the three groups after the first (ANCD+SR 100%, BGC+SR 90%, DAC+SR 85%) or the final pass (ANCD+SR 100%, BGC+SR 90%, DAC+SR 95%). The mean number of passes in each treatment group was ANCD+SR 1.0, BGC+SR 1.1, and DAC+SR 1.2 ($p=0.16$).

For fibrin-rich clots, the recanalization rate after the first pass was higher for ANCD+SR (90%) than for BGC+SR (50%; $p<0.01$) or DAC+SR (77%; $p=0.18$). The final pass recanalization rate was also significantly higher for ANCD+SR (100%) than for BGC+SR (63%; $p=0.01$) or DAC+SR (87%; $p=0.04$). In addition, the mean number of passes was lower with ANCD+SR (1.1) than with BGC+SR (1.7; $p<0.01$) or DAC+SR (1.3; $p=0.01$).

Recanalization rates according to clot type and model are shown in figure 3 and table 1. When studying the first-pass recanalization rate in relation to tortuosity, ANCD+SR versus other treatment arms showed higher rates in the moderate model ($p=0.02$) and a non-significant trend in the severe model ($p=0.07$) (figure 4). A logistic regression model adjusting for treatment arm, clot type, and tortuosity model showed that both RBC-rich clots (OR 8.1, 95% CI 1.6 to 13.5) and ANCD+SR (OR 3.9, 95% CI 1.01 to 15.8) were independent predictors of first-pass recanalization.

DISCUSSION

Our in vitro study showed that the ANCD thrombectomy device in combination with a stent retriever achieved higher rates of complete recanalization in a lower number of passes compared with two other standard widely used thrombectomy techniques. The study demonstrated similar success rates in various degrees of anatomical tortuosity and, in contrast to the compared techniques, we did not observe any decrease in performance rate for fibrin-rich clots, commonly considered difficult to retrieve.¹³ In fact, both RBC clots and the use of ANCD+SR emerged as independent predictors of first-pass recanalization.

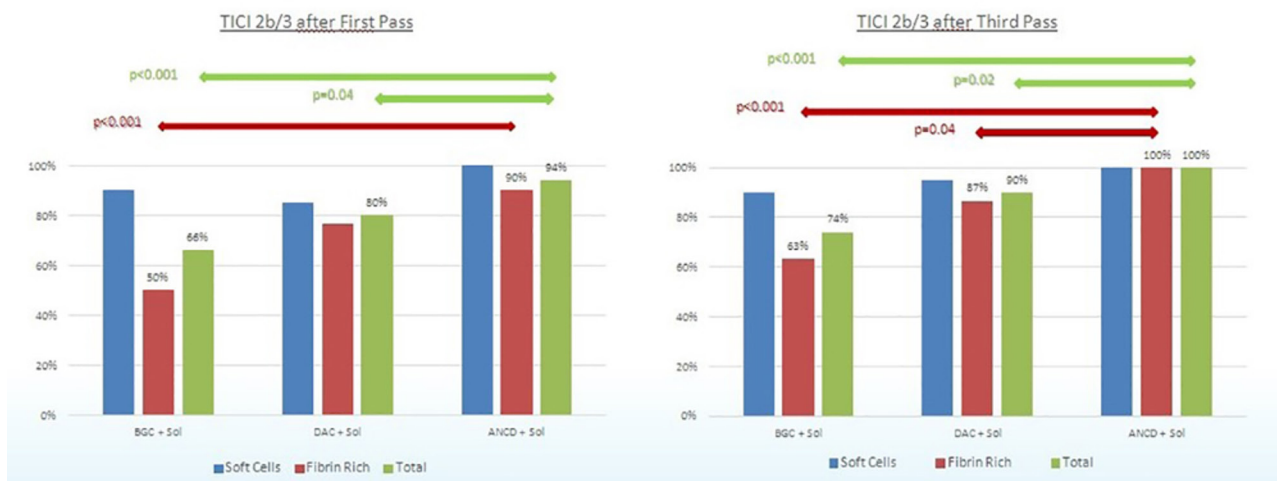

Figure 3 Recanalization rates after first and last pass according to clot type and treatment group.

Mechanical thrombectomy is today regarded as standard of care for acute stroke in relation to large vessel occlusions.¹⁹ Successful and rapid recanalization has been demonstrated to correlate with improved clinical outcome. Rates of successful recanalization (mTICI 2b–3) vary widely and range between 58% and 92% in prospective studies.¹ A recent analysis from the Hermes Collaboration population showed overall rates of complete recanalization (eTICI 2c–3) as low as 32%,² indicating that there is still substantial room for improvement both in the technical skills of the interventionalists and in the efficacy of the thrombectomy devices.

During the last 25 years the features of thrombectomy devices and the techniques used in patients with acute stroke have substantially evolved and better results have been progressively achieved.²⁰ Better primary and ancillary devices together with improved selection protocols led to the first five positive trials that definitively launched EVT as an effective treatment for acute stroke patients with LVO around the world.¹ However, lack of complete recanalization and clot fragmentation with distal

embolization^{21–23} are still common problems despite the availability of effective thrombectomy tools such as stent retrievers, distal aspirating catheters, and BGCs. During a thrombectomy process the occluding clot must fit in an extracting catheter that represents the exit door from the arterial system. As the clot is often larger than the diameter of the accepting catheter, the clot must compress and elongate and these morphological changes may subsequently cause clot stripping, fragmentation, and potential distal embolization.¹⁰ To avoid these unwanted phenomena, BGCs¹² capable of creating flow arrest or large-bore distal access catheters have been developed.¹¹ In our study we compared the efficacy of such devices with the ANCD in combination with a stent retriever. The ANCD is a construction of two catheters that incorporates a coated self-expanding funnel. When the funnel is deployed in the occluded artery proximal to the clot it combines the beneficial effects of flow restriction and maximum aspiration/ingestion diameter, as the funnel adapts to and becomes as wide as the diameter of the lodging artery. The stent retriever in combination with local distal aspiration only needs to mobilize the clot a few centimeters to reach inside the funnel. Once copped and protected in the funnel, the entire clot-containing construct can subsequently be easily pulled out, thereby reducing the risk of fragmentation and distal embolization.

In addition to potentially lessening the risk for distal embolization, the ANCD may facilitate the retrieval, not least for resistant high-friction fibrin-rich clots notorious for causing retrieval difficulties resulting in many failed thrombectomy attempts. Fewer attempts and thereby a shorter procedure time will most likely be beneficial for the patient as a reduction in the number of passes has been associated with better patient outcomes. The flow restriction created by the ANCD is also restricted to the affected artery, minimizing the hemispheric flow arrest created by the use of a BGC positioned and inflated in the ICA. In addition, it is reasonable to assume that the power of aspiration will increase if the occluding catheter is positioned just proximal to the clot since there are in that case no large side branches between the catheter and the clot.²⁴ When aspiration is performed from a BGC in the ICA, the aspiration force in the MCA may be lessened as it is shared with large branches such as the anterior cerebral artery or the posterior communicating artery. The resultant aspiration power transmitted to the clot located in the MCA is consequently decreased compared with direct aspiration in the MCA, especially if it is combined with flow restriction.

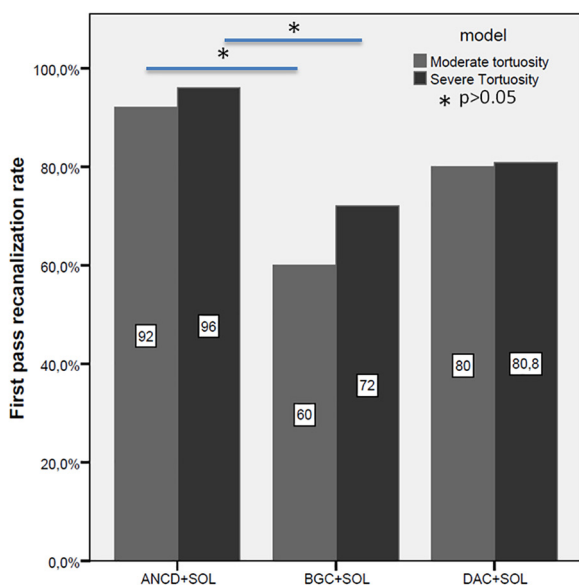


Figure 4 Recanalization rates after first pass according to replica model and treatment group.

In this study we selected, as predicates, approved devices widely used in current practice. It is possible that different stent retriever sizes, models, or aspiration methods may have produced different results. This study was not designed to assess the incidence of small clot fragments embolizing into distal arteries beyond the MCA-M2 branches. Future studies specifically designed for this purpose²⁵ will assess if the ANCD is also beneficial in this respect. The deliverability of the funnel was progressively improved during the development of the device and at this stage could be consistently deployed at the MCA level. However, it is possible that in real patients with severe tortuosities the delivery of the funnel could only be achieved after deploying the stent retriever over the clot which will anchor the system and assist the delivery. The real safety and efficacy of the ANCD device will have to be determined in human studies.

CONCLUSION

In in vitro three-dimensional phantom models replicating an M1-MCA occlusion, ANCD+SR showed significantly better recanalization rates in a smaller number of passes than other commonly used combinations of devices.

Contributors SS, IC, HV, AR, IG, TA, RN, TJ, MR: study design, data acquisition, critical revision of the manuscript. MR drafted the manuscript. All the authors made a substantial contribution to the conception and design of the work, revised the paper for intellectual content, and gave final approval of the version to be published.

Funding Anaconda Biomed provided funding for the study.

Competing interests SS, IC, HV, AR, and IG are employees of Anaconda Biomed. MR and TJ are shareholders in Anaconda Biomed. TA and RN are clinical consultants for Anaconda Biomed. RN is a consultant/advisory board member for Stryker Neurovascular and Covidien. Stryker Neurovascular (Trepo-2 trial principal investigator—modest; DAWN trial principal investigator—no compensation; TREVO registry steering committee—no compensation), Medtronic (SWIFT trial steering committee—modest; SWIFT-Prime trial steering committee—no compensation; STAR Trial Angiographic Core Lab—significant), Penumbra (3D Separator trial executive committee—no compensation), Neuravi (ARISE-2 steering committee—no compensation), Genentech (physician advisory board—modest), Allm Inc (physician advisory board—no compensation). TA is a consultant for Ablynx, Amnis Therapeutics, Anaconda, Cerenovus/Neuravi, Medtronic, Rapid Medical. MR is a consultant for Cerenovus, Medtronic, Stryker, Apta Targets and Vesalio. TJ is a consultant for Stryker Neurovascular (PI DAWN-unpaid); Ownership Interest: Anaconda; Advisory Board/Investor: FreeOx Biotech; Advisory Board/Investor: Route92; Advisory Board/Investor: Blockade Medical, Consultant; Honoraria: Cerenovus.

Patient consent for publication Not required.

Provenance and peer review Not commissioned; externally peer reviewed.

Data sharing statement The data that support the findings of this study are available from the corresponding author on reasonable request.

REFERENCES

- Goyal M, Menon BK, van Zwam WH, et al. HERMES collaborators. Endovascular thrombectomy after large-vessel ischaemic stroke: a meta-analysis of individual patient data from five randomised trials. *Lancet* 2016;387:1723–31.
- Liebeskind DS, Bracard S, Guillemin F, et al. HERMES Collaborators. eTICI reperfusion: defining success in endovascular stroke therapy. *J Neurointerv Surg* 2019;11:433–8.
- Saver JL, Goyal M, van der Lugt A, et al. HERMES Collaborators. Time to treatment with endovascular thrombectomy and outcomes from ischemic stroke: a meta-analysis. *JAMA* 2016;316:1279–88.
- Alawieh A, Pierce AK, Vargas J, et al. The golden 35 min of stroke intervention with ADAPT: effect of thrombectomy procedural time in acute ischemic stroke on outcome. *J Neurointerv Surg* 2018;10:213–20.
- Zaidat OO, Castonguay AC, Linfante I, et al. First pass effect: a new measure for stroke thrombectomy devices. *Stroke* 2018;49:660–6.
- Kleine JF, Wunderlich S, Zimmer C, et al. Time to redefine success? TICI 3 versus TICI 2b recanalization in middle cerebral artery occlusion treated with thrombectomy. *J Neurointerv Surg* 2017;9:117–21.
- Machi P, Jourdan F, Ambard D, et al. Experimental evaluation of stent retrievers' mechanical properties and effectiveness. *J Neurointerv Surg* 2017;9:257–63.
- Yoo AJ, Andersson T. Thrombectomy in acute ischemic stroke: challenges to procedural success. *J Stroke* 2017;19:121–30.
- Gunning GM, McArdle K, Mirza M, et al. Clot friction variation with fibrin content; implications for resistance to thrombectomy. *J Neurointerv Surg* 2018;10:34–8.
- Madjidyar J, Hermes J, Freitag-Wolf S, et al. Stent-thrombus interaction and the influence of aspiration on mechanical thrombectomy: evaluation of different stent retrievers in a circulation model. *Neuroradiology* 2015;57:791–7.
- Alawieh A, Chatterjee AR, Vargas J, et al. Lessons learned over more than 500 stroke thrombectomies using ADAPT with increasing aspiration catheter size. *Neurosurgery* 2018 [e pub ahead of print].
- Brinjikji W, Starke RM, Murad MH, et al. pact of balloon guide catheter on technical and clinical outcomes: a systematic review and meta-analysis. *J Neurointerv Surg* 2018;10:335–9.
- Fennell VS, Setlur Nagesh SV, Meess KM, et al. What to do about fibrin rich 'tough clots'? Comparing the Solitaire stent retriever with a novel geometric clot extractor in an in vitro stroke model. *J Neurointerv Surg* 2018;10:neurintsurg-2017-013507—2010.
- Kyun Kim J, Woo Choi J, Se Choi B, et al. Sum of the curve indices for estimating the vascular tortuosity of the internal carotid artery. *Neurointervention* 2009;4:101–6.
- Chueh JY, Wakhloo AK, Gounis MJ. Effectiveness of mechanical endovascular thrombectomy in a model system of cerebrovascular occlusion. *AJNR Am J Neuroradiol* 2012;33:1998–2003.
- Duffy S, Farrell M, McArdle K, et al. Novel methodology to replicate clot analogs with diverse composition in acute ischemic stroke. *J Neurointerv Surg* 2017;9:486–91.
- Chueh JY, Wakhloo AK, Hendricks GH, et al. Mechanical characterization of thromboemboli in acute ischemic stroke and laboratory embolus analogs. *AJNR Am J Neuroradiol* 2011;32:1237–44.
- Nikoubashman O, Alt JP, Nikoubashman A, et al. Optimizing endovascular stroke treatment: removing the microcatheter before clot retrieval with stent-retrievers increases aspiration flow. *J Neurointerv Surg* 2017;9:459–62.
- Powers WJ, Rabinstein AA, Ackerson T, et al. 2018 Guidelines for the early management of patients with acute ischemic stroke: a guideline for healthcare professionals from the American Heart Association/American Stroke Association. *Stroke* 2018;49.
- Spiotta AM, Chaudry MI, Hui FK, et al. Evolution of thrombectomy approaches and devices for acute stroke: a technical review. *J Neurointerv Surg* 2015;7:2–7.
- Caroff J, King RM, Arslanian R, et al. Microcatheter navigation through the clot: does size matter? *J Neurointerv Surg* 2019;11:271–4.
- Kim BM. Causes and solutions of endovascular treatment failure. *J Stroke* 2017;19:131–42.
- Lee DH, Sung JH, Kim SU, et al. Effective use of balloon guide catheters in reducing incidence of mechanical thrombectomy related distal embolization. *Acta Neurochir* 2017;159:1671–7.
- Lally F, Soorani M, Woo T, et al. In vitro experiments of cerebral blood flow during aspiration thrombectomy: potential effects on cerebral perfusion pressure and collateral flow. *J Neurointerv Surg* 2016;8:969–72.
- Chueh JY, Puri AS, Gounis MJ. An in vitro evaluation of distal emboli following Lazarus Cover-assisted stent retriever thrombectomy. *J Neurointerv Surg* 2017;9:183–7.